

SameDay Dental Implants® & Teeth A Surgical & Prosthodontic Protocol

By Costa Nikolopoulos Oral & Maxillofacial Surgeon (S.A.) & Petros Yuvanoglu Specialist Prosthodontist (U.S.A.)

The original Branemark protocol advocated the use of a two stage surgical approach where the turned (smooth) implants were buried for several months under the mucosa. With the advent of surface enhanced and tapered implants the protocol later evolved into a one stage approach.

Several clinicians then proceeded to immediately load these one stage implants with good success provided good primary stability (more than 45Ncm) was achieved at time of implant placement and provided micro-movements could be limited to 100µm. Ample reports have been published on immediate loading of dental implants showing an initial unloaded period of 3-6 months is not necessary. From a patient's point of view the reduction of treatment time between implant placement & installation of a functional prosthesis leads to increased patient satisfaction & treatment acceptance. This gain in time for the patient implies an economical benefit especially for professionally and/or socially active patients.

High treatment acceptance and patient satisfaction are the most important advantages of immediate loading and immediate function.

Surgical Protocol

The surgical protocol of immediate loading of dental implants with same day teeth is based on the following:

Avoid Bone Grafts

This is in line with Prof. P.I. Branemark's philosophy of "Lesser Surgery to Treat More Patients" (Fig 1).

With increased costs and patient morbidity due to bone grafting, an increased patient resistance to implant treatment has been noted. An alternative method of treating implant patients who have suboptimal bone volume without bone grafting is made possible by using:

- 1) Angled implants in a tilted manner placed into available bone anterior and posterior to the maxillary sinus (Fig 2).
- 2) Wider and appropriately shaped implants placed into immediate extraction molar sockets thereby avoiding socket or sinus grafting (Fig 3).

High Primary Stability

An important factor for immediate loading success is high primary implant stability (greater than 45Ncm) which can be achieved by using a surface enhanced tapered implant design to enhance lateral compression of bone.

By underprepping, high insertion torque and primary stability can be achieved even in cases of decreased bone density such as is often the case in maxillary alveolar bone and as well as in osteoporotic patients. Primary stability can easily be measured during implant placement with a torque wrench (Fig 4).

If 45Ncm insertion torque is not achieved, the implant should be removed and without further bone preparation a 1mm wider implant is placed.

This usually results in adequate primary stability of 45Ncm for immediate loading. If 45Ncm insertion torque is still not achieved then again the implant can be removed and replaced with an even wider diameter implant if the available bone width permits. This usually results in adequately high insertion torque and primary stability greater than 45Ncm. If despite this, adequate primary stability is not achieved then immediate loading is not recommended.

Prosthodontic Driven Implant Placement

By using a silicone key of the facial surfaces of the existing teeth (Fig 5) or a silicone key of a diagnostic wax up (Fig 6), it is possible to place the implant in the correct position and angle so that the screw access hole can exit in the correct place to allow for screw retention.

In order not to lose significant orientation, extractions are not performed all at once prior to implant placement but are rather performed one at a time followed by implant placement so that the silicone key can direct the implant surgeon (Fig 7).

It is very often necessary to use an implant with a built in angle of 12°, 24° or even 36° so that the case can be screw retained.

Screw retention is an absolute requirement for biological reasons (to avoid risk of inflammation due to excess cement) as well as the ease of handling of immediate loading in a surgical environment.

Bite registration is started prior to extraction of all the teeth in the full mouth/arch case so as not to lose the centric relation and vertical dimension (Fig 8). The remaining extractions are then performed, further implants are placed and the bite registration is completed with addition of bite registration material onto the remaining healing caps.

One Abutment One Time

After bone milling to remove any interfering bone, in multiple implant cases transmucosal multi-unit abutments are placed on the implants and torqued to 45Ncm at the time of surgery.

These abutments are placed and torqued onto a "clean" implant platform with no interfering bone or soft tissue and are never removed again.

Scientific research shows less bone loss, better bone levels and peri-implant soft tissues when

the transmucosal abutments are placed at time of surgery and never removed (Fig 9).

Healing caps are then placed on the multi-unit abutments (Fig 10). After abutment placement, at the same surgical appointment, the impression is taken at abutment level and provisional acrylic screw retained fixed teeth are placed in the same day as the implant surgery.

In single implant cases the healing abutment is placed directly at implant level. An implant impression is taken and six hours later a full ceramic/zirconia screw retained crown is then connected and torqued to 45Ncm directly on to the implant without an intermediate/transmucosal abutment (Fig.11). No multi-unit abutment is indicated or placed in the single implant case as the multiunit abutment has no anti-rotation feature.

Flapless/Minimal Flap Surgery

In extraction cases no mucoperiosteal flap is reflected. The integrity of the extraction socket walls is inspected and assessed with a 15mm or 20mm periodontal probe placed into the extraction socket. Palpation of the extraction socket walls is performed with the probe (Fig 12) and this is complemented by good vision with magnifying loops and light illumination.

In healed sites where possible the "punch" technique is used (Fig 13). Alternatively minimal flaps are raised where indicated.

This flapless/punch technique/minimal flap approach results in minimal or no soft tissue changes thereby allowing the restorative dentist/prosthodontist to proceed with the provisional acrylic screw retained teeth in the same day and permanent ceramic screw retained teeth in 1 week in the case of multiple implants. In the case of the single implant the permanent full Zirconia screw retained tooth can be delivered in 6 hours on the same day.

Number of Implants

In edentulous cases 4 to 6 im-

plants (figs 14 & 15) are placed per arch depending on:

- 1) Bone volume & quality
- 2) Implant length & diameter
- 3) Implant distribution (A-P spread)
- 4) Patient's age
- 5) Patient's finances (cost to benefit ratio)

Prosthodontic Protocol

The Prosthodontic protocol of SameDay Dental Implants & Teeth is focused and designed around the patient's needs. It's fast, efficient and doesn't compromise quality. The patients are never left without teeth for more than six hours. As a result treatment acceptance is high.

All implants with good primary stability (>45Ncm) are immediately loaded with screw-retained teeth. For single implant cases, the final all ceramic screw retained tooth is fabricated and delivered to the patient within six hours. For multiple implants cases, temporary screw retained acrylic teeth are fabricated within six hours and the permanent screw retained all ceramic or metal ceramic teeth are delivered one week later.

Timing of Immediate Loading

Dental implants either should be loaded the earliest possible (never exceed ten days after surgery) or alternatively two months after placement. This is because the so-called initial "primary stability" (mechanical stability) that an implant has, starts to drop gradually and the implant become more prone to failure if forces are applied. Fortunately, simultaneously a "secondary stability" (Osseointegration) starts to build up. The sum of the two "stabilities" which is demonstrated on the stability graph (Fig. 16), gives us the "total stability". As a golden rule implants ideally should never be disturbed during the "stability dip" period.

Preoperative Preparation

In order to achieve this protocol, preoperative screening and detailed surgical and prosthodontic

> Page 28



Fig 1. Dr. Costa and Dr. Petros in line with Prof. Branemark's philosophy of "Lesser Surgery to Treat More Patients".

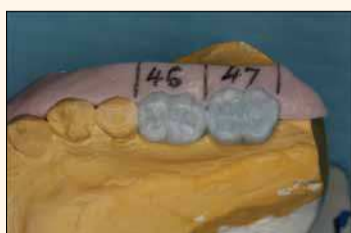

Fig 6. Silicone key of a diagnostic wax up.

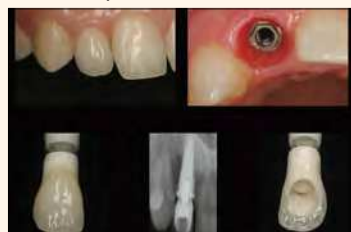

Fig 11. The single implant with a Zirconia screw retained crown.

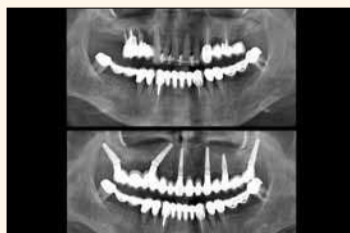

Fig 2. Angled implants placed into available bone anterior and posterior to the maxillary sinus.

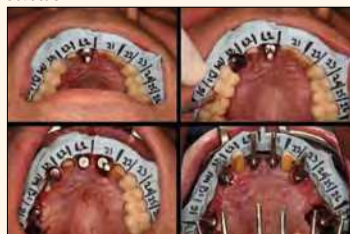

Fig 7. The silicone key can direct the implant surgeon.

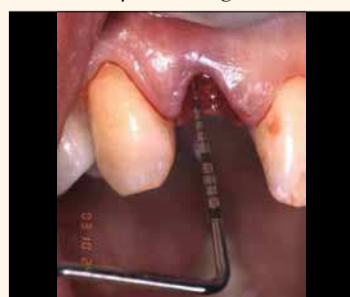

Fig 12. Palpation of the extraction socket walls with a periodontal probe.

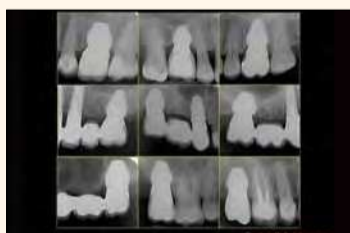

Fig 3. Immediate molar replacement implants.

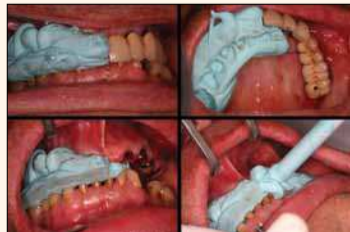


Fig 8. Bite registration is started prior to extraction of all the teeth and is completed with addition of bite registration material onto the remaining healing caps.

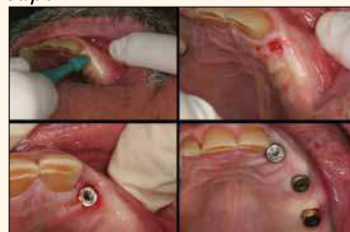

Fig 13. In healed sites where possible the "punch" technique is used.

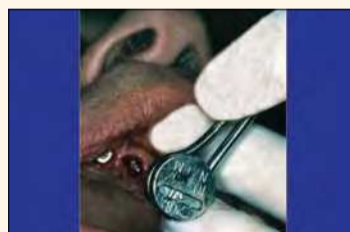

Fig 4. 45Ncm Primary Stability measured during implant placement.

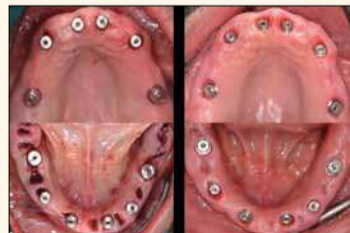

Fig 9. Good peri-implant tissues with "One Abutment One Time" approach.

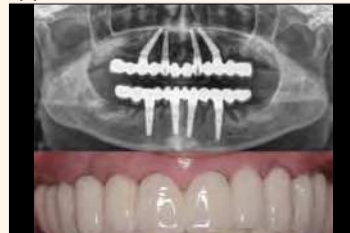

Fig 14. All-On-4

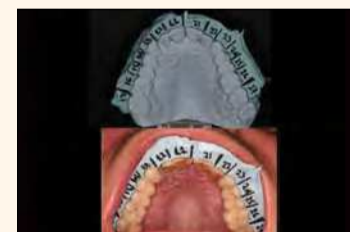

Fig 5. Silicone key of the facial surfaces of the existing teeth.

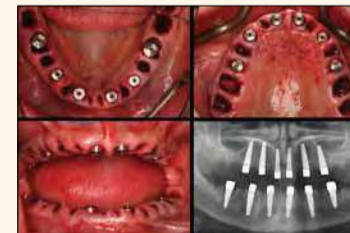

Fig 10. Healing caps placed on abutments.

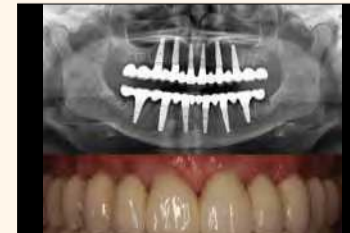

Fig 15. All On-6

< Page 27

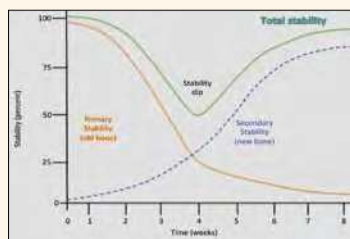


Fig. 16. Implants should not be loaded during the "Stability Dip" period.

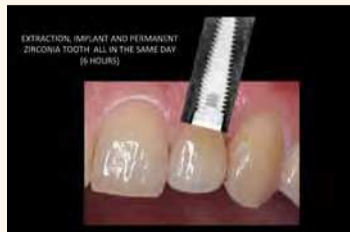

Fig. 20. Periapical x-ray, verifying perfect fit of the all ceramic crown onto the implant.

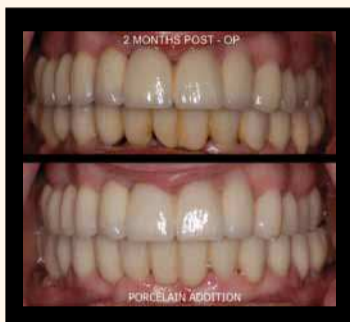

Fig. 25. Adaptation of the final prosthesis onto the mature soft tissues, two months after surgery.

dontic treatment planning is imperative.

From the prosthodontic point of view, each patient's smile, mouth and occlusion are evaluated with the help of photos and videos (dynamic picture). Impressions are taken and the diagnostic models are mounted. If needed, the digital smile design (DSD) (Fig. 17) concept is used in order to proceed with a diagnostic wax-up. From the waxed models, "silicone keys" of the buccal/lingual surfaces of the teeth, are fabricated, which will be used during the surgery to guide the implant placement.

Impression During Surgery

An impression of the implants is taken during the surgery, either at implant level for single implants or at abutment level for multiple implant cases.

It's imperative to make sure that the impression copings are seated all the way onto the implants (periapical x-rays can be used for verification).

For the impression, the open tray technique is recommended with the use of very hard addition cured silicon impression material.

At the end of each surgery, pre-operative impressions, impression of the implants and bite registration are provided to the dental lab (Fig. 18). The dental technician mounts the implant models and starts the fabrication of the implant prosthesis.

Single Implant Reconstruction

For single implant cases the permanent, screw retained, all ceramic zirconia teeth are fabricated immediately with the use of prefabricated zirconia cores (Fig. 19). They are available in different sizes and shapes, according to the prosthetic platform of the implant in use and the available prosthetic space, between the adjacent teeth.

While the patient is waiting in the recovery room the dental technician grinds and shapes

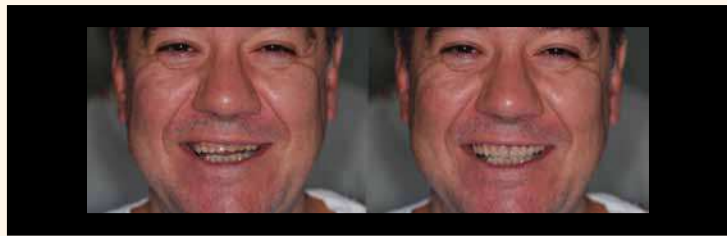

Fig. 17. Before/After Digitally Designed Smile

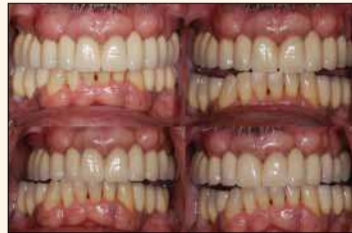

Fig. 21. The Mutually Protected Occlusion.

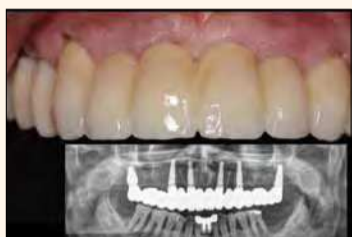

Fig. 26. Final Full Contour ZIRCONIA prosthesis on implants.

the zirconia core and eventually bakes the porcelain on to it. Four to six hours later the permanent tooth is placed into the mouth of the patient and the prosthetic screw is torqued down to 45Ncm. A periapical x-ray helps to verify the perfect fit (5µ) on to the implant (Fig. 20). Occlusion is checked and verified with the help of 8µ thick "schimstock" articulating paper. The prosthetic access hole is obturated with a two layered filling (teflon tape + opaque composite resin) to allow easy access for retrievability in the future but simultaneously excellent esthetics.

Two months later upon maturation of the soft tissues and osseointegration, an additional x-ray is taken and if needed modifications are made to the prostheses.

Multiple Implants Reconstruction

1) Temporary Teeth

For multiple implant cases (three unit bridges to full mouth reconstructions), the temporary screw retained acrylic teeth are fabricated by the in house dental lab within five to six hours and are delivered immediately to the patient on the same day.

Providing the temporary teeth immediately, isn't only a great service to the patient but is also the best "diagnostic tool" for the restorative dentist to record all necessary information for the fabrication of the permanent teeth. If needed modifications are easily made to the acrylic teeth either directly in the mouth or in the dental lab.

The patient should be evaluated for esthetics, phonetics and occlusion. Midline, plane of occlusion and buccal corridors are established. The "S" and "F" sounds are checked. The occlusal scheme is adjusted. For extensive cases the "mutually protected occlusion" (Fig. 21) is established which means that in centric occlusion, all teeth are touching but the posterior teeth have slightly heavier contacts compared to the anterior and on lateral and protrusive excursive movements the anterior teeth are touching/guiding and there are no posterior "working" or "non-working" interferences (anterior guidance). X-rays are taken in order to verify the passive fit of the prosthesis.

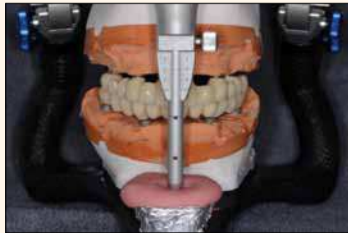

Fig. 22. The Anterior Custom Made Guiding Table.

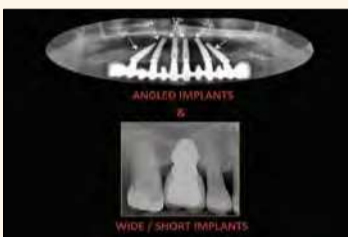

Fig. 27. SameDay Dental Implants® & Teeth with Angled and Wide implants.

Once all necessary modifications are made and the patient is satisfied, we need to convey all newly established parameters to the dental technician. This is achieved by:

- taking photos and videos to record the esthetic result, in the mouth and
- using the so-called "Clinical Remounting Procedure", in the laboratory.

Alginate impressions and bite registration are taken from the temporary teeth, which are removed from the mouth and remounted again on the articulator. From the newly remounted temporary teeth the dental technician fabricates:

- a series of silicon keys which will guide him to fabricate the permanent teeth and ii) an "Anterior Custom Made Guiding Table" (fig 22) which will allow him to reproduce the occlusal scheme of the temporary teeth to the permanent teeth.

Twenty minutes later the temporary teeth are placed again in the mouth of the patient and the prosthetic screws are torqued to 20 Ncm. He is instructed not to bite hard onto the acrylic teeth and oral hygiene instructions are provided to him.

2) Permanent Teeth Fabrication

The dental lab, with the help of i) the interchangeable implant and temporary models, ii) the silicon keys, iii) the anterior custom made guiding table, iv) the photos and v) the videos starts to fabricate immediately the permanent screw retained porcelain teeth.

The permanent teeth need to be ready in one-week's time and should have perfect fit onto the implants. This is one of the most important prerequisites for optimal implant longevity.

The material of choice, used by our dental lab, for the past 20 years, is porcelain fused to metal. The fabrication of the metal ceramic prosthesis involves a series of technique sensitive procedures. Inevitably in each step, small "5 dimensional inaccuracies" are introduced into the prosthesis. The sum of these inaccuracies is never zero. As a result, at the end of the fabrication procedure, the final prosthesis will never have a perfect fit onto the implants.

The use of the "Passive Abutment" (Fig. 23), which is a tita-

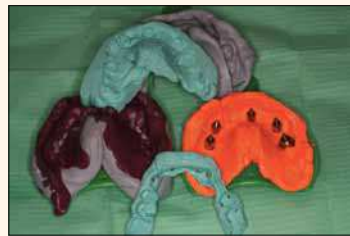


Fig. 18. Preoperative and implant impressions, bite registrations and silicone keys, right after surgery.

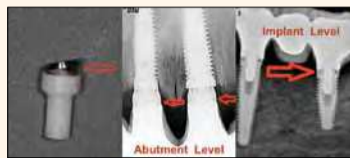

Fig. 23. The Passive Abutment.

nium machine-cut interfacial component/cylinder, offsets all the 3D inaccuracies, provided that the implant model is accurate. The passive abutment is cemented by the dental technician onto the fitting surface of the prosthesis, in the lab. The master implant model is used as a blueprint for the cementation. Based on our experience over the past 15 years of using passive abutments, the metal try-in procedure is not needed, thus speeding up the fabrication of the final prosthesis.

3) Placement of the Permanent Teeth

One week after the implant surgery the patient returns for the placement of the permanent teeth.

The temporaries are removed, the prosthetic platform of the implants is cleaned, dried and immediately the permanent teeth are screwed onto the implants.

There is a big benefit having to work only with "one piece screw retained" (Fig. 24) prosthesis. There are no multiple custom abutments to be positioned first, the retrievability of the "one piece prosthesis" makes adjustments much easier, there is no excess cement to deal with during cementation that can cause significant complications if left accidentally under the immature tissues.

Fitting of the prosthesis is assessed with x-rays. Like with the temporary teeth all parameters (esthetic, phonetics, occlusion) are checked again and adjustments are made. The prosthetic screw is torqued down to 32Ncm and the prosthetic access holes are obturated. A night guard is provided and the patient is instructed to use it every night. Oral hygiene instructions are demonstrated and their importance is emphasized.

Follow up

Two months later the osseointegration of the implants is radiographically and mechanically evaluated. In case of soft tissue recession, a pick up impression of the prosthesis is done. A new soft tissue model is fabricated and the dental technician can add porcelain accordingly (Fig. 25). The patient is followed up every six months for the first two years and thereafter according to his/her oral hygiene level.

Complications

The majority of the prosthodontic complications are porcelain fractures/chipping. These are easily repaired by removing the teeth and rebaking the porcelain.



Fig. 19. Prefabricated Zirconia Cores in different shapes and sizes.

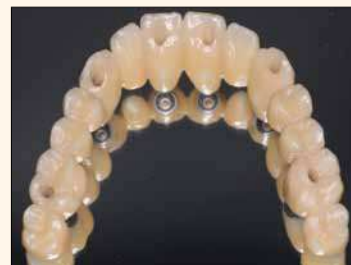

Fig. 24. The "One Piece Screw Retained" Prosthesis.

CAD/CAM Advancements

Recently in order to eliminate this problem, at SameDay Dental Implants® Clinic, CAD/CAM full contour zirconia screw retained implants prostheses are used in selected patients (Fig. 26). Only the front 6 teeth are layered (buccally) with porcelain to optimize esthetics and passive abutments (titanium) are utilized to eliminate zirconia to titanium wear problems.

Even though zirconia is a technique sensitive material, the first results (one year) are very promising. However, only time will tell, if zirconia will be the material of choice. The advancements in digital impressions and CAD/CAM technology will further reduce the manufacturing time but most importantly will increase the accuracy and quality of the dental prostheses.

Conclusion

By using tapered angled implants as well as wide immediate molar replacement implants in a prosthodontically driven fashion it is possible in most cases to avoid bone grafts, achieve high primary stability and treat patients with implants and passively fitting, screw retained teeth all in the same day (Fig 27).

This reduction in treatment time, immediate function and cost saving leads to high patient satisfaction and increased treatment acceptance by patients. ^{DT}

Contact Information



Dr. Costa Nicolopoulos BDS cum laude, FFD (SA) MFOS



Dr. Petros Yuvanoglu DMD summa cum laude, Cert. Prosth (TUFTS, USA)

SameDay Dental Implants®
Brånemark Osseointegration
Center Dubai
Building 59, Dubai Health Care
City
tel: +971(0)44275010
email: info@samedayme.com
web: www.samedayme.com